Perio-prosthetic management in aesthetic area using "cut back" lithia-disilicate-based (LS2) all ceramic crowns

C.Coraini, S. Rossi, F. Buono, P. Raschiotti, C. Casto, T. Mascarello, L. De Micheli

Istituto Stomatologico Italiano,
Scientific Director:
Dr. Luca De Micheli
CAD-CAM Prosthetic Department,
Head: Dr. Cristian Coraini
Via Pace, 21
20122 Milan - Italy

aim

The purpose of the work was to evaluate the behaviour of the tissues around full-ceramic lithium disilicate crowns in the upper frontal group, and to correct a frontal lower dental malposition by means of poreclain laminate veneers, in one complex perio-prosthesis case

methods and materials

In the upper jaw, after the first provisionals and the bone-resective periodontal surgery to restore the correct dento-periodontal relationship and re-create the symmetry between the gingival parables, during the healing period we placed the second provisionals. The diastema present in the first and second quadrant was closed by performing two composite inlays on the elements 1.4 and 1.6, and by means of a classic metal-ceramics bridge on 2.4 x 2.6. The group from 1.3 to 2.3, after the adhesive post-endodontic reconstructions (silica fiber posts), received all-ceramic lithium disilicate crowns (cut-back technique, CAD E-max Diadem). Finally, we have performed 3 feldspathic porcelain laminate veneers both to close the existing diastema and to realign the crowded elements 3.1, 4.1 and 4.2, and an additional composite veneer mesially to the item 3.2.

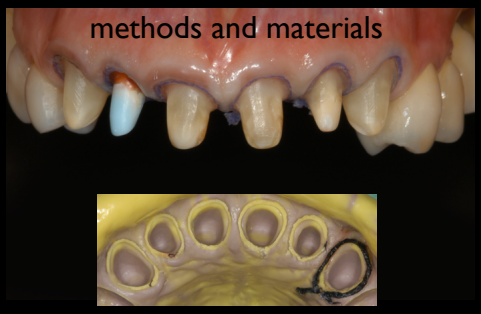

results

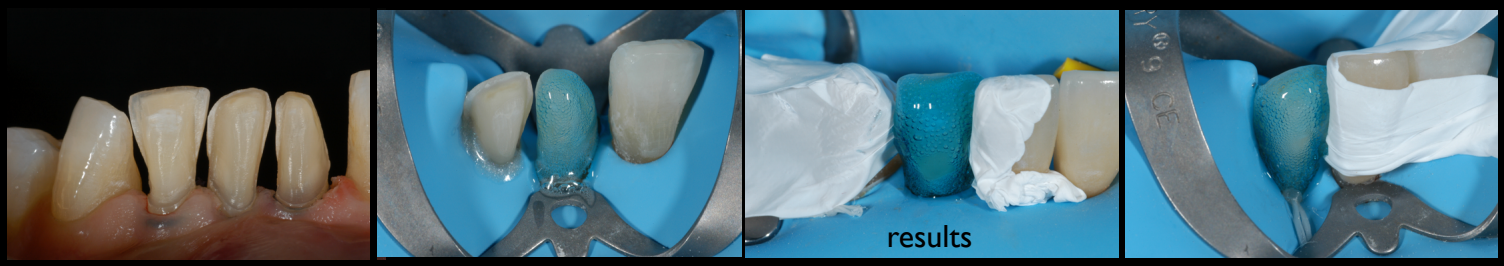

The relationship between biological width, placement and type of the marginal prosthetic preparation, gingival biotype and the working area are factors that must be carefully considered, independently from the type of material used to perform the restoration.

conclusions

We were able to process and adhesively cement the lithium disilicate crowns on the items from 1.3 to 2.3. We have found a very high level of gingival health, the absence of inflammation, a very natural and pleasant capability to transmit light both through the artifacts, and deep in the gums around the restoration themselves.